

ACUTE RHEUMATIC FEVER: CURRENT SCENARIO IN INDIA

4 : 7

IB Vijayalakshmi, Bengaluru

INTRODUCTION

Acute rheumatic fever (ARF) and its long term sequel, rheumatic heart disease (RHD) is a major health problem in children, adolescents and young adults.¹ Despite the tremendous progress made in cardiology, the menace of morbidity and mortality due to acute rheumatic fever and its consequences remain very high in India.² Because of the preoccupation of the cardiologist with adult cardiac disease like ischemic heart disease, the problems of ARF/RHD have been sidelined and studies on prevalence, treatment and prevention receive only scant attention and only exotic palliative methods such as balloon mitral valvotomy, valve/replacement have become the centre stage in India.^{3,4}

Precise diagnosis of acute rheumatic fever has presented problems since Hippocrates, who provided the first written description of arthritis in man in 400 BC.⁵ Lack of specific criteria had led to diagnostic chaos until the Jones criteria in 1944.⁶ Despite the Jones criteria and four revisions and modifications,⁷⁻⁹ ARF is either under diagnosed leading to nearly 50% of established RHD not receiving prophylaxis or over diagnosed by depending on traditional characteristic auscultatory findings for diagnosing carditis. Unfortunately modern facility like echocardiography (ECHO) is not included in Jones criteria, despite the fact that ECHO can help to diagnose carditis more frequently than auscultatory findings.^{9,10} Early diagnosis of ARF though difficult is very important to prevent the serious consequences in young.

DISEASE BURDEN

In India, rheumatic fever is endemic and remains one of the major causes of cardiovascular disease, accounting for nearly 25-45% of the acquired heart disease. The annual incidence of rheumatic fever is 100-200 times greater than that observed in developed countries and fluctuates between 100-200 per 1,00,000 children of school age (from 5 years to 17 or 18 years depending on the study). India is in the phase of 'epidemiological transition'. On one hand there is a substantial burden due to RHD for the treatment of which enormous money is spent, on the other hand the government resources are scarce to treat and prevent the disease. More than 20,382 cases of RHD (10% of total admission) were admitted at Sri Jayadeva Institute of Cardiovascular Sciences and Research, in Bengaluru (1998-2010). The approximate cost of treatment was more than Rs 100 million (\$ 2,272,727) in the last 12 years. In cardiology department from April 1994 to August 2010, more than 14,560 cases percutaneous transluminal balloon commissurotomy (PTMC) were done, out of which 6550 cases were below the age of 20 years and the youngest patient was 6 years old. Despite the subsidized rates the cost for management of mitral stenosis has been Rs3,02,50,000 (\$ 68,75,000) and valve replacement has cost Rs 80 million (\$18,18,181) over the last few years in our hospital alone.¹¹ Not only the cost of treatment is phenomenal, the morbidity and mortality is also enormous. Hence "Prevention is better than cure" is very apt for rheumatic fever.

EPIDEMIOLOGY

The prevalence of ARF/RHD in India has been reported to be varying from very infrequent to very high levels depending upon the source of information e.g., Registrar General, population sources, and hospital admissions. Recent data from India suggest that a large number of cases of ARF/RHD are still seen frequently in young children under the age of 10 years.¹² Though lately, many published studies

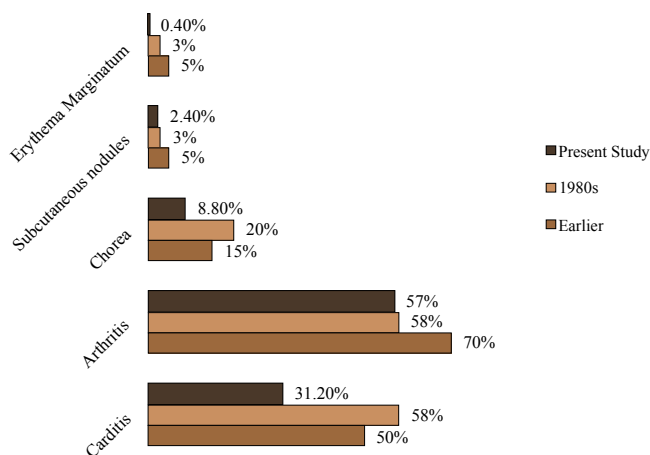


Fig. 1 : Changing profile of acute rheumatic fever




Fig. 2A: Mitral valve verrucae (nodules) on autopsy

and ICMR data are suggestive of decline in disease prevalence in the society. Recently, one of the published studies, entirely based on echocardiography has refuted the previous claims by showing very high prevalence of RHD.¹³ On the contrary, a large study from the Uttar Pradesh, so called BIMAROU states (Bihar, Madhya Pradesh, Rajasthan, Orissa and Uttar Pradesh) screening 5000 school going children with echocardiography had shown relatively low incidence (0.5/1000).¹⁴ Are these studies the real representation of the menace of rheumatic fever in India?

Again we can take an analytical view of school surveys as they are inherently biased and will miss older patients with RHD. In areas where ARF and RHD are on the decline, most patients with RHD tend to be older. Moreover, school drop outs, sick kids or child labour (urban slums) are likely to be missed in these surveys. None of studies done in 5-15 age groups have targeted the children working in factories / farms etc. None of them are from Bihar, Orissa, and Madhya Pradesh (BIMAROU). At least one such echo based study from Rajasthan is quoting high prevalence rate in randomly selected population. Other studies, liberal to age but are biased otherwise like those which are based on registries have the potential to capture all age groups but are heavily dependent on referral mechanisms. Hospital based statistics have serious

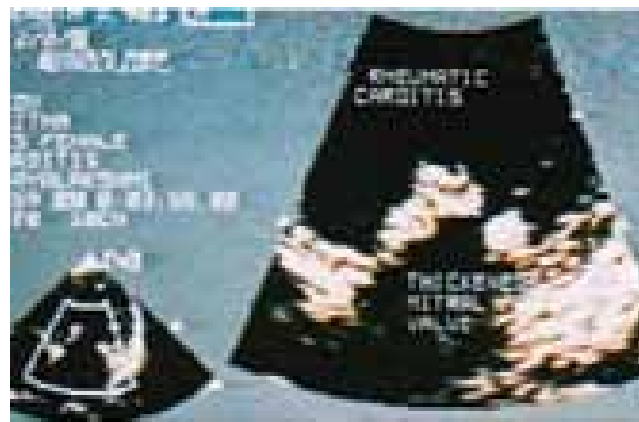

Fig. 2B: Echo showing nodules on AML and PML (equivalent to verrucae)

limitations because only the most seriously affected are represented.¹⁵

India has its share of vulnerable population afflicted with ARF and RHD like any other developing countries. If the current data from school centric studies are to be believed, there is an encouraging trend towards decline in the prevalence (< 1/ 1000).^{14,16-18} Should we see this data sceptically or should we welcome it as good change in rheumatic profile without significant intervention? Undisputedly, rural is more affected than the urban population. According to the data, most comparative studies have reported a substantially higher prevalence in rural regions.¹⁹⁻²¹ Because of serious limitations in the health care delivery systems, the magnitude of the problem may remain unrecognized in remote places.

CLINICAL PROFILE

The major manifestations of ARF are: i) Carditis ii) Polyarthritiis iii) Chorea iv) Erythema marginatum v) Subcutaneous nodules. The clinical profile of acute rheumatic fever seems to be changing (Figure 1). Clinical diagnosis of carditis was noted in at least 50% of acute rheumatic fever in the past. There seems to be a declining incidence of carditis. The diagnosis of carditis that is considered a major criteria in acute rheumatic fever depends on the clinical and traditional auscultatory findings.⁴ Out of 164 cases of clinically diagnosed cases of carditis only 141 cases (85.9%) showed echocardiographic evidence of carditis/ valvulitis with beaded appearance of valves, which is equivalent to rheumatic nodules/verrucae on the valves in autopsy (Figure 2A and 2 B). The remaining 23 cases (14%) had no carditis. In fact they had functional murmur, fever, tachycardia, anaemia. Two cases had congenital heart disease like atrial septal defect and sub aortic membrane.²²

DIAGNOSIS OF CARDITIS: AUSCULTATION VS. ECHOCARDIOGRAPHY:

All the diagnostic guidelines on ARF/RHD, gives emphasis on auscultatory findings. The auscultation is becoming a dying

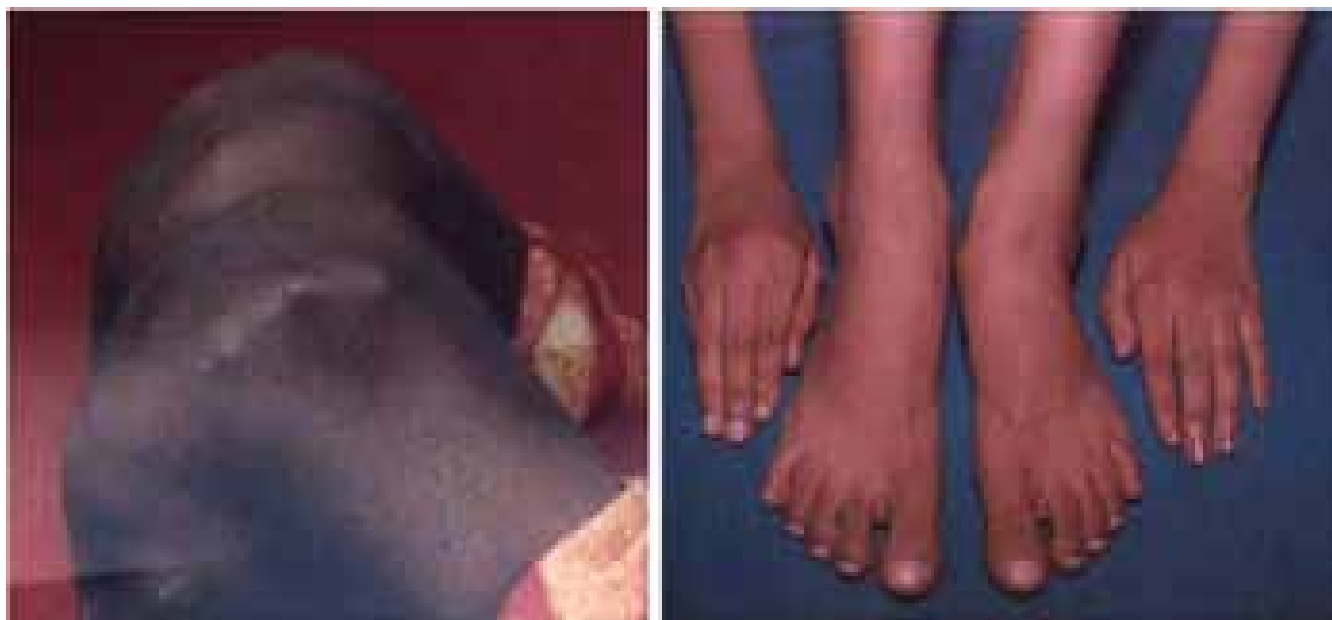

Fig. 3A and B: Subcutaneous rheumatic nodules

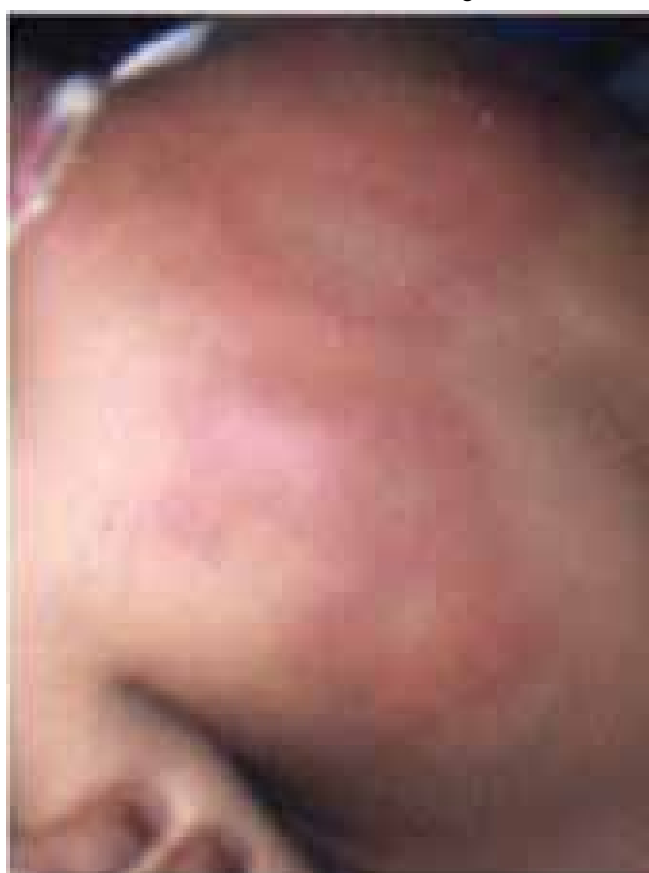

Fig. 4: Erythema marginatum

art in India among the young physicians. In this situation, ECHO remains the best bet. Despite many arguments, for and against the inclusion of ECHO findings as diagnostic criteria,

it is not acknowledged by any of the prevailing guidelines. (Jones criteria updated 1992, WHO revised criteria 2004, IAP working group on pediatric ARF/RHD 2007).^{9,23,24} Carapetis et al²⁵ published their evidence based review and accepted the ECHO based diagnosis of subclinical carditis as major criteria. Moreover, ECHO is being used extensively these days and practically the diagnosis of valvulitis is based on ECHO findings.

JOINT INVOLVEMENT

In our country, it has been observed but never corroborated that many patients who presented with established RHD, had history of arthralgia or monoarthritis rather than classical polyarthritis. Flitting type of migratory polyarthritis was present in 239 patients (52.87%), whereas migratory polyarthralgia was seen in 213 cases (47.12%) in our study. Out of these 213 cases of arthralgia, 38 patients (17.84%) had clinical evidence of carditis.²²

SUBCUTANEOUS NODULE

SCN is a major criteria and a high rate of coexistent carditis. Subcutaneous nodules (Figure 3A and B) were seen in only 7 cases (2.4%) in our study.²² All these patients had high titres of antistreptolysin O, ranging between 800 and 1600 IU, but C-reactive protein was positive in only 4 cases. All seven patients had both clinical and echocardiographic evidence of carditis. They can be induced artificially by using autologous buffy coat from blood for the diagnosis of rheumatic activity.

ERYTHEMA MARGINATUM

It is transient and may not be present at the time the physician is examining the patient. This skin manifestation of ARF is a major criterion which is more often is missed due to darker

colour of skin in Indian population (Figure 4). The incidence is very low and was seen in only 2 (0.4%) of patients of our study.²² Both had clinical and echocardiographic evidence of carditis.

RHEUMATIC CHOREA

Chorea is one manifestation which presents late and in isolation without any positive minor criteria. It may have subclinical carditis. In view of this etiological cause of chorea becomes a diagnosis of exclusion. Rheumatic chorea was found in 40 (8.85%) of patients, with 8 having bilateral chorea, in our study.²² In one patient, the chorea lasted for one year, and in another it had recurred after 2 years. Two other screened siblings of one child with chorea showed no evidence of acute rheumatic fever at the time of screening, but developed rheumatic chorea after 3 months. The titres of antistreptolysin O were negative in 17 cases (42.5%), but ranged from 400 to 800 International Units in the remaining 23 cases. The mean duration of onset of chorea after the initial fever was 3 months. It was surprising to find that 28 of the patients with rheumatic chorea (70%) had echocardiographic evidence of valvar involvement, although this had not been detected clinically.²²

The physician's clinical recognition of ARF has very important implications for the patient's management and prognosis. RHD places heavy economic burden on the healthcare system in low and middle income families in developing countries, because of the costs of medical, surgical and non-surgical treatment and also because it is a disease of young adults, who are the most economically active group of any population. Management is complex and involves different levels of care. Hence, early and precise diagnosis of carditis in ARF, though difficult is very important to prevent the serious consequences, morbidity and mortality in the young. But, unfortunately ARF despite its distinctive clinical features, is a syndrome without pathognomonic symptoms, signs or laboratory tests. The modern new technology like ECHO can fill in that grey area for the diagnosis of carditis.

Clinical diagnosis of carditis usually depends on detecting a) myocarditis b) pericarditis and c) valve regurgitation.

a. Myocarditis

Myocarditis is suspected clinically by gallop sounds on auscultation, unexplained cardiomegaly and unexplained congestive heart failure (CHF). These features are nonspecific and can occur in any conditions causing myocarditis or CHF. But the ECHO can detect the features of carditis in ARF and help to make a precise diagnosis and detect the cause of CHF.

b. Pericarditis

Pericarditis is diagnosed by auscultating pericardial rubs

or detecting unexplained pericardial effusion. The pericardial rub is transient and occurs for only few hours in a day. Hence, when a clinician is examining the patient, the rub may not be present or even if present the clinician may not recognize it, as many youngsters would not have heard pericardial rub at all in the medical school. Hence, the pericarditis may go unrecognized. Pericardial effusion occurs most commonly in tubercular pericarditis in India. A case of tubercular pericarditis with fever, arthralgia, cardiomegaly, tachycardia, pericardial rub and raised ESR may be misdiagnosed as ARF with carditis, if one depends upon Jones criteria. Whereas ECHO features of carditis in ARF with pericardial effusion can distinguish pericardial effusion of tubercular etiology, which has normal valves with no regurgitation of the valves.

c. Regurgitation

The valve regurgitation is diagnosed by auscultating soft blowing pansystolic murmur of mitral regurgitation (MR) at the apex or early diastolic murmur of aortic regurgitation (AR) in the aortic or Erb's area. But many younger clinicians are unable to recognize gallop sounds, pericardial rub and murmurs. Recent studies have shown that clinical auscultation may be a dying art, especially in countries where ARF is declining. The residents detect significant mitral regurgitation in less than half of the cases.^{26,27} Skill levels do not significantly improve with increasing periods of clinical training and even cardiology fellows have not demonstrated superior diagnostic ability for the identification of cardiac murmurs.²⁷ The auscultatory skills have declined compared with those reported in the 1960s.²⁸ All this suggests that the clinical diagnosis of carditis in ARF may not be made with sufficient confidence. In our study MR, AR and tricuspid regurgitation (TR) was more often detected by ECHO than clinically.²⁹

PITFALLS IN JONES CRITERIA

The precise diagnosis of carditis in ARF is eluding the clinician because of many pitfalls in Jones criteria.

1. It is difficult to diagnose ARF when carditis is the only manifestation of the disease particularly in a recurrence.
2. When patient has sub clinical carditis the clinicians fail to detect clinically
3. Clinically apparent carditis is present but supportive minor criteria are not fulfilled.³⁰
4. When previous cardiac status is unknown it is not possible to know in a new case whether the findings are due to acute carditis or it is recrudescence or it is established old case of RHD.

- In cases of polyarthralgia, which is a minor criterion, if the patient is neglected and not evaluated for ARF, they would go undiagnosed, and could end up with RHD, allegedly without any past history of ARF, as the patient and the parents would have long forgotten the joint pain.

Due to these lacunae in Jones criteria the diagnosis of 'carditis' in ARF is eluding the clinicians. ECHO, Doppler examination identifies valvular regurgitation not detectable with clinical examination.³¹⁻³⁶ ECHO allows visualization of valve structure, and allows detection of unrelated causes of valve regurgitation, such as myxomatous valve with mitral valve prolapse.

GOALS OF ECHO INTERROGATION:

Amongst the various manifestations of ARF, carditis is the only one that can cause death during the acute stage of the disease or may lead to long term morbidity and mortality. It is very pertinent to realize that ECHO is the only investigating modality by which we can assess carditis and formulate the management strategies.

- ECHO can help in precise and early diagnosis of carditis in ARF. As timely management can make the heart normal in 35-40% of cases of ARF and in remaining children the secondary prophylaxis can prevent the recrudescence of rheumatic activity.
- Echo can prevent 'overdiagnosis' of carditis by depending on the traditional clinical auscultatory findings, which could be fallacious and lead to unnecessary drug-ging and psychological impact on the children and their family.
- Regular check up with non invasive ECHO can help to evaluate the status of RHD and decide for elective balloon valvuloplasty (PTMC) for mitral stenosis and timely decision for valve repair/replacement. This can reduce the morbidity and mortality, before the patient develops CHF.

ECHOCARDIOGRAPHY VS. CLINICAL EXAMINATION

The MR in ARF is usually mild to moderate. The assessment of mechanism and severity of MR has prognostic significance. The various mechanisms of MR are: i) valvulitis, ii) valve prolapse, iii) annulitis with annular dilatation, iv) ventricular enlargement v) rarely chordal rupture.

Clinically we can only detect the regurgitation but all these mechanisms causing MR cannot be made out by clinical examination. In our prospective study,²² 492 consecutive patients diagnosed clinically as ARF (according to Jones criteria) were examined thoroughly by the paediatricians, who had used appropriate laboratory tests. ECHO was performed in detail by the well trained and experienced echocardiographer,

who was unaware of the clinical diagnosis (double blind). Only of 59.4% of clinically diagnosed carditis by well qualified pediatricians had ECHO evidence of carditis.²² That means even the senior experienced clinicians end up with over diagnosis when they rely only on clinical assessment and Jones criteria. The patients with over diagnosis of carditis (40.6%) actually had functional murmurs, tachycardia, fever, anaemia and congenital heart diseases! On the other hand in the patients with polyarthralgia (70%) which is a minor criterion, ECHO evidence of carditis / valvulitis was seen in 46.9% of cases and the pediatricians had overlooked the carditis leading to under diagnosis of carditis in patients with arthralgia. This shows that in regions where ARF is endemic if arthralgia is taken as minor criteria and ECHO is not done, then it leads to gross underdiagnosis.

Traditionally clinical manifestation of MR and AR are diagnostic of carditis in ARF. The carditis is rarely diagnosed clinically in the absence of valve regurgitation and precordial auscultation has been the traditional modality for the diagnosis of MR and AR. In our study, 239 cases of MR were detected by ECHO, but an audible murmur of mitral regurgitation was detected by cardiologist only in 144 cases.²⁹ (Table 1) That means 95 patients with pathological MR would have remained undetected, and would not have received penicillin prophylaxis, if not for echocardiographic interrogation. This suggests that the clinical diagnosis of rheumatic carditis may not be made with sufficient confidence. Echo Doppler examination identifies valvular regurgitation not detectable with clinical examination.²⁹⁻³⁶ Others have concluded previously³⁷ that early echocardiographic interrogation is very important in all children suspected to have ARF, especially as MR can be demonstrated by colour flow mapping in absence of cardiac murmur (Figure 5).

The pulse and colour Doppler Echo provide a method to detect minor degree of pathological regurgitation without characteristic clinical signs.³⁴ Doppler echocardiography is more sensitive than clinical assessment in the detection of carditis in ARF, and can also contribute to the early diagnosis.^{33, 38} Clinicians detected the early diastolic murmur of aortic regurgitation clinically in only 11 cases, but significant aortic regurgitation was detected by ECHO in 60 cases. Similarly, the systolic murmur of tricuspid regurgitation was clinically detected only in 9 cases, but echocardiographic interrogation detected tricuspid valve thickening, beading and regurgitation in 60 patients.²⁹ (Figure 6)

All these patients had other evidence of rheumatic carditis.²⁹ Features like thickened valves, beaded appearance, hyper echogenic submitral structures (Figure 7A, 7B and 8). This shows that the carditis cannot be reliably diagnosed in the absence of clinical signs of valve regurgitation in especially subclinical carditis. This may lead to significant under detection of carditis in ARF. Unfortunately there is no single laboratory

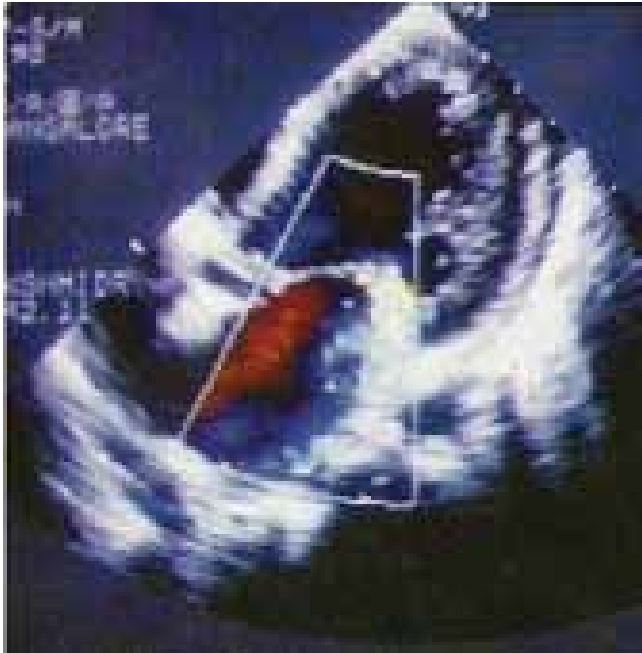

Fig. 5: Pancarditis with mitral regurgitation

Table 1: Comparison between clinical and ECHO detection of MR, AR and TR

	Clinical	Echo
MR	144	239
AR	11	60
TR	9	60

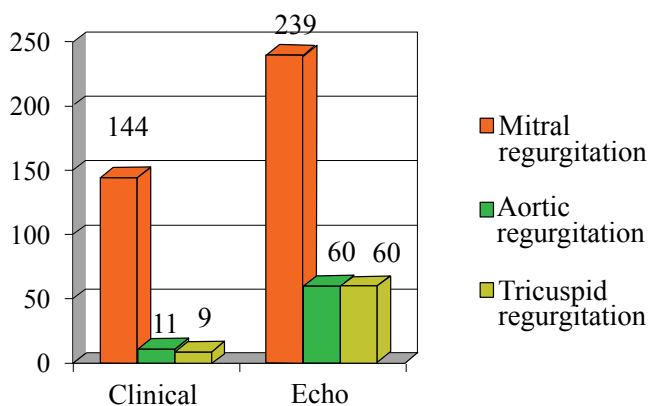


Fig. 6: Clinical and echocardiographic comparison in mitral, aortic and tricuspid valve regurgitation

test that definitely establishes the diagnosis of carditis in ARF. Whereas ECHO can diagnose carditis precisely and accurately, especially subclinical carditis / valvulitis can be detected only by ECHO and Doppler.

ECHO IS THE KEY

In many ECHO and Doppler studies,^{10, 39-41} most cases of rheumatic carditis are not severe enough to be symptomatic

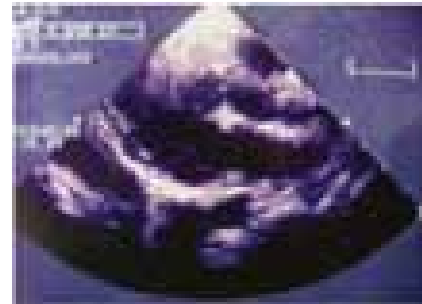

Fig. 7A: Thickened mitral valve (AML 6 mm) in PLAX view

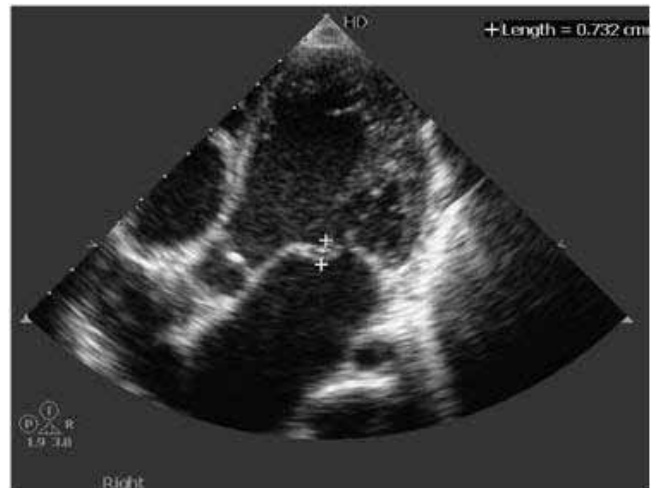

Fig. 7B: ECHO in the apical five chamber view shows thickened leaflets of the aortic and mitral valves with hyperechogenic submitral structures.

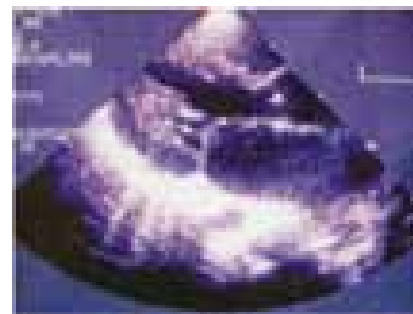

Fig. 8: Echogenic submitral structures in PLAX view

and the diagnosis of isolated carditis previously depended on auscultation alone. Eighty percent or more cases of MR that are detected by ECHO are also readily diagnosed by experienced physicians by auscultation alone. The remaining “subauscultatory” cases are those with the mildest degree of mitral or aortic regurgitation. If rheumatic in origin, more than 80% of these valvular lesions are likely to heal without scarring. Moreover, the sensitivity of ECHO may detect degrees of valvular regurgitation within the physiologic range, and not functionally significant, especially in children and in very thin, active individuals with highly elastic valve leaflets and rings.

Table 2: Echocardiographic investigations

<i>M-mode interrogation</i>	
•	Dimensions of left atrium, aorta and their ratio
•	Left ventricular dimension in diastole and systole
<i>Cross-sectional interrogation in long axis, four-chamber, five-chamber and short axis</i>	
•	Thickness of the valves, with less than 3 millimetres taken as normal, and more than 4 millimetres as thickened
•	Beaded appearance, especially of mitral, tricuspid and aortic valves
•	Prolapse of mitral valve, particularly the aortic leaflet
•	Decreased or increased mobility of the valves
•	Hyperechogenicity of the thickened submitral apparatus
•	Chordal tears to mitral leaflets
•	Pericardial effusion
•	End diastolic volume, end systolic volume and ejection Fraction
<i>Colour Doppler interrogation</i>	
•	Establishment of mitral, aortic and tricuspid regurgitation
•	Differentiation of physiological and pathological regurgitation
Colour jet in two planes extending well beyond valvar leaflets, with pulsed Doppler confirming the velocity signal, holosystolic for mitral regurgitation and holodiastolic for aortic regurgitation, was taken as indicative of pathological regurgitation	

Although the Jones criteria specify clinical auscultatory evidence for the diagnosis of mitral and aortic insufficiency, like our study,²⁹ more and more reports discuss subclinical carditis, in which MR is noticeable only on ECHO. Several investigators have concluded that two dimensional echocardiography using colour and pulsed Doppler imaging are useful in identifying subclinical lesions. But some say the use of echocardiography to diagnose carditis remains controversial. Hence ECHO findings do not signify an increase in the incidence of RF, but rather improve the detection of subclinical carditis. Therefore to call it as carditis of ARF, valve regurgitation alone is not enough.^{9,41} But if echo features of RF are used in support then regurgitant lesion of RF can be distinguished from functional as well as regurgitation of other conditions.²⁹ Therefore ECHO is the key for precise diagnosis of carditis.

But what do the textbooks say about the ECHO in ARF? There is only one sentence – ‘The patients with isolated manifestations of ARF such as arthritis / chorea may have ‘subclinical’ carditis – stretching of chordae tendinae with prolapse of anterior mitral leaflets’.³¹

Therefore prospective double blind study was conducted to know the various features of carditis in ARF²² And depending on these Echo features Vijaya’s Echo criteria was evolved and its efficacy was tested in a prospective double blind study.²⁹

ECHOCARDIOGRAPHIC INVESTIGATIONS (TABLE 2)

i. M-mode: The M-mode in patient with carditis shows

Table 3: The incidence of various echocardiographic features²²

Sl. No.	Type of Involvement	No. of Cases	%
1.	Mitral thickness >4 mm	132	93.62
2.	Mitral regurgitation grade I – II	118	83.69
3.	Mitral valve prolapse (MVP)	80	56.74
4.	Rheumatic nodules	38	26.95
5.	Aortic regurgitation (AR)	31	21.99
6.	Tricuspid regurgitation (TR)	31	21.99
7.	Pancarditis.	13	9.22
8.	Pericardial effusion (PE)	13	9.22
9.	Chordal tear	4	2.84

dilated left atrium (LA) and left ventricle (LV). Normally left atrium and aorta (AO) have almost the same dimension. But in carditis of ARF the LA is dilated and LA to AO ratio is altered. The thickened mitral and / aortic leaflets ≥ 4 mm (normal ≤ 3 mm) is seen very often. Sometimes valve thickening could be 9-10mm. (Figure 7A & B). Rarely tricuspid valve also could be thickened.

ii. 2 D ECHO: The 2 D Echo shows increased end diastolic volume (EDV) and end systolic volume (ESV) and the ejection fraction (EF) is reduced marginally. The incidence and various ECHO features of carditis in ARF are as given in Table 3.

In carditis of ARF the mitral valve is the most commonly affected valve. The inflamed oedematous valve is seen on ECHO as thickened ≥ 4 mm in 93.6% of cases²² with reduced mobility and hyperechogenicity of submitral structures is seen. The small vegetations on the free edge of valve cusp, indicating endocarditis seen in autopsy (Figure 9 A), are seen as thickened irregular nodular leaflets on Echo (Figure 9 B). These nodules are seen just proximal to the free edge of mitral valves, where the cusps come into apposition, at the site of maximum natural trauma. These nodules on body and tip of mitral leaflets do not have chaotic motion like vegetations. They may disappear on follow up. It is thought that these nodules may be equivalents of verrucae seen at autopsy in patients who died of ARF.⁴¹

The beaded appearance of mitral valve on ECHO are nothing but the ECHO images of small thrombi that form on the valve at the edge ((Figure 10A). These ridge or a row of small pink nodules seen on ECHO as beaded appearance of the valve (Figure 10B)

Vijaya’s Echo Criteria for the diagnosis of carditis/subclinical valvulitis was evolved by giving 2 points for each of the eight ECHO features of carditis as shown in Table 4. The cases with an Echo score of ≥ 6 out of 16 were taken as ECHO positive, so as to avoid over diagnosis of MR.

Score of ≥ 6 is diagnostic of rheumatic carditis



Fig. 9A: Autopsy picture of carditis shows thickened irregular nodules on the free edge of MVon ECHO

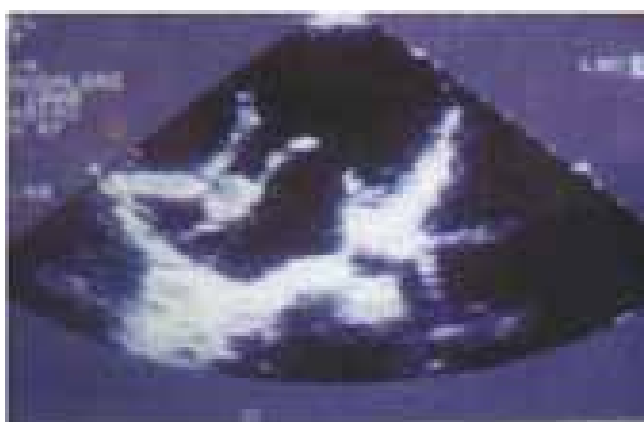

Fig. 9B: Nodules on body and tip of mitral leaflets do not have chaotic motion like vegetations

HOW SPECIFIC AND SENSITIVE IS VIJAYA’S ECHO CRITERIA?

‘Vijaya’s ECHO criteria’ proposed for the precise diagnosis of both ‘clinical carditis’ and ‘sub clinical valvulitis’ has 81% sensitivity with 93% specificity.²⁹

The often raised question is, “Should Echo Carditis Be Accepted as a Major Manifestation in the Jones Criteria in the Absence of Clinical Evidence of Carditis?”⁷ When literature is reviewed none of the studies has come out with echo criteria for diagnosis of carditis in ARF. Most of the studies found regurgitation lesions are common in ARF and suggested for its inclusion in Jones criteria.^{33,36 42-45}

PHYSIOLOGICAL VERSUS PATHOLOGICAL REGURGITATION

It is very important to distinguish the physiological mitral regurgitation from pathological regurgitation. The pathological valvular regurgitation can be easily differentiated from physiological regurgitation by demonstrating

- i. Substantial colour jet in two planes extending well be-

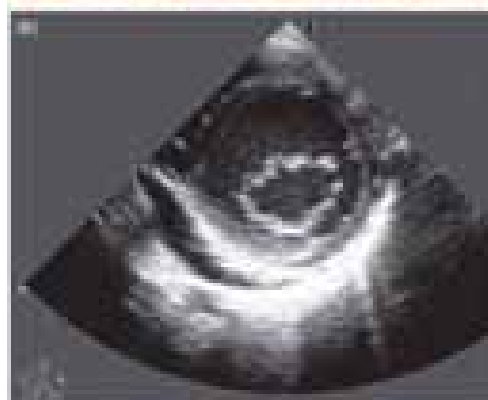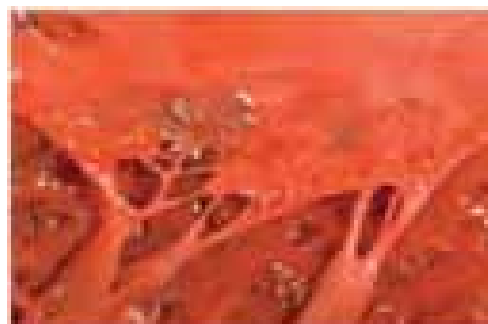


Fig. 10A & B: Row of small pink thrombi at the edge of the valve at autopsy (A) and compared to ECHO in parasternal short axis view showing beaded appearance of the valve (B)

Table 4: Vijaya’s Echo Criteria

Sl. No	Echo feature	Score
1	Mitral valve and aortic valve thickness ≥ 4 mm	2
2	Increased echogenicity of submitral structures	2
3	Rheumatic nodules (beaded appearance)	2
4	Mitral valve prolapse /aortic valve prolapse/tricuspid valve prolapse	2
5	Mitral regurgitation and / aortic regurgitation/tricuspid regurgitation	2
6	Reduced mobility of valves	2
7	Chordal tear	2
8	Pericardial effusion	2
Total score		16

yond valve leaflets (extending > 1 cm beyond coaptation point).

- ii. Colour jet of MR passes over the posterior wall of (LA), it is a high velocity signal in pulse Doppler, with a well defined, dense, high velocity spectral envelope, holosystolic mitral regurgitation (Figure 11)
- iii. The pathological MR are, graded as trivial, grade I, II, III.

Mitral regurgitation can be demonstrated by colour flow mapping even in the absence of cardiac murmur. Moreover

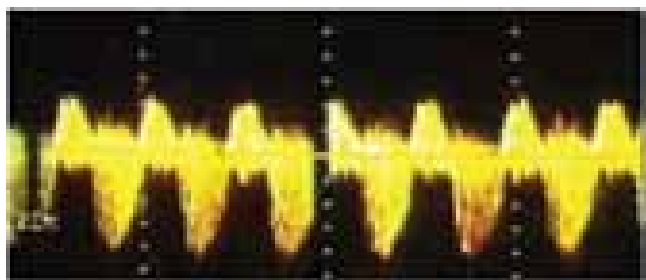


Fig. 11: Colour Doppler shows well defined, dense, high velocity holosystolic spectral envelope

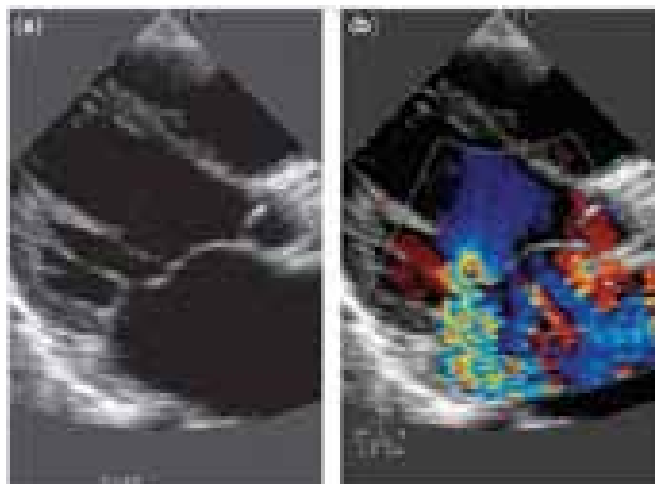


Fig. 12: The images from a 12 years old girl with acute rheumatic fever show thickened leaflets of the aortic and mitral valves, which have a beaded appearance, hyper-echogenicity of the submitral structures, mitral valvar prolapse with mitral regurgitation, giving an overall echocardiographic score of 10, with 2 points each for the mitral valvar prolapse, regurgitation, thickened leaflets, hyperechogenicity of the submitral structures, and the beaded appearance.

unless valve regurgitation is associated with other features like “thickened valves, beaded appearance, hyper echo submitral structures”, with an echo score of ≥ 6 , it is not taken as significant and pathological. (Figure 12 A & B)

It is important to differentiate torn chordae, with mitral regurgitation, from vegetations on mitral valve (MV). Vegetations are more likely on LA side and torn chordae are on LV side. However one has to interpret the ECHO with the clinical background. Pancarditis with pericardial effusion (PE), dilated LV, chordal tear of both anterior and posterior mitral leaflet with mitral valve prolapse (MVP), mitral regurgitation is shown in Figure 13. Mitral valve and aortic valve can show active valvulitis. The valve is thickened and displays small vegetations like “verrucae which are embedded in the body of the valve, hence do not have the chaotic motion of the vegetations”.

The details of incidence of various ECHO features of carditis

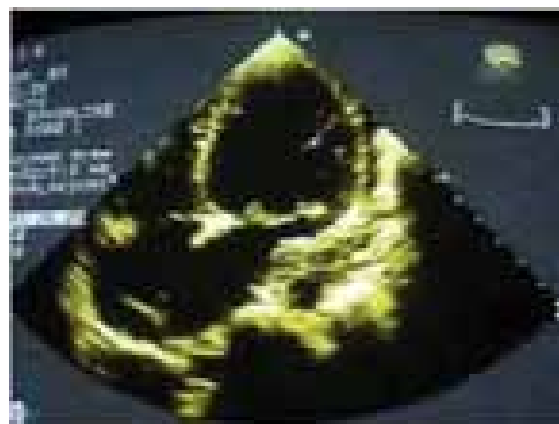

Fig. 13: Apical four chamber view shows, pericardial effusion, dilated LV, chordal tear of both anterior mitral leaflets and posterior mitral leaflet with mitral valve prolapse (MVP), mitral regurgitation

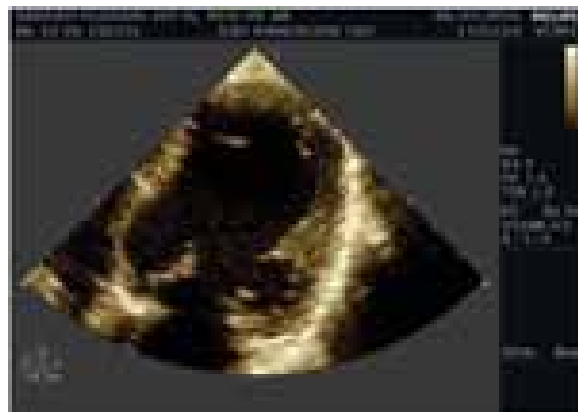

Fig. 14: 2-D ECHO in 12 year old boy of ARF with severe MR on high dose of steroids without any improvement had chordal tear

in our study²⁹ are given in order of occurrence. The severity of mitral regurgitation depends on the severity of carditis. 2D Echo and Doppler has prognostic significance. MR in carditis ARF is mild to moderate. Rarely MR could be severe in which case it could be due to chordal tear and that can be detected with ECHO precisely (Figure 14).

DOES ECHOCARDIOGRAPHY PERFORM SUPERIORLY IN THE DIAGNOSIS OF RHEUMATIC CARDITIS?

The answer is an irrefutable yes. Therefore apart from valvar regurgitations, other features of rheumatic carditis in ECHO and colour Doppler findings should be accepted as a major criterion for the diagnosis of carditis in rheumatic fever. Therefore there is no doubt that if echocardiography is used as a primary diagnostic modality, and is included in Jones' criteria it will change the epidemiological face of ARF and RHD completely. Usefulness of modern facility like ECHO is not included in Jones criteria despite the fact that echo

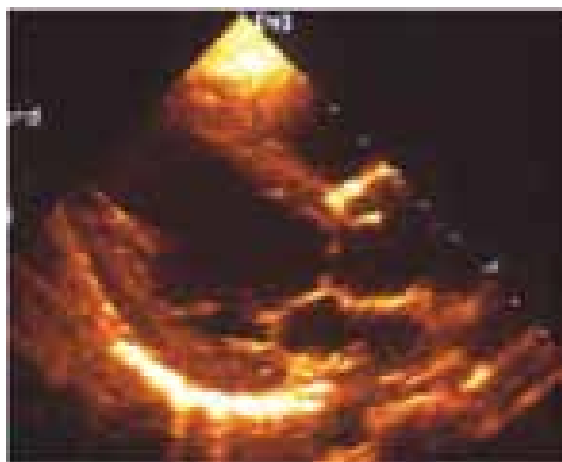

Fig. 15: Parasternal long axis view of 12 years old boy with a discrete subaortic membrane who was wrongly treated as ARF with carditis

can diagnose carditis more frequently and accurately than traditional auscultatory findings early and precise diagnosis of ARF with carditis / subclinical carditis / valvulitis can prevent serious consequences, morbidity and mortality in young and ECHO is of great help in this endeavour.

ECHO supports the diagnosis of carditis in ARF, allowing the identification of important valve lesions and exclusion of non-rheumatic causes of valvular involvement.²³ The usual mechanism of mitral regurgitation in ARF is valvulitis, valve prolapse, annulitis, ventricular enlargement or rarely chordal rupture. All these details cannot be made out by clinical examination. As accurate and precise diagnosis is required for deciding the management strategy, ECHO is very essential to know all the details.

A 12 years old boy with a discrete subaortic membrane (Figure 15), wrongly diagnosed as having ARF with carditis, had been treated with steroids by his paediatrician. He subsequently developed tubercular meningitis, as the primary complex flared up subsequent to the steroids therapy. This episode demonstrates graphically the potential error in diagnosis can be made if clinical carditis, if unconfirmed by echocardiography, is taken as a major criterion for acute rheumatic fever when combined with two minor criterions such as fever and a raised ESR. The case can be diagnosed precisely using echocardiography, thus avoiding false positive diagnosis.

On the other hand, in 88 of our patients with polyarthralgia, almost half of those with this minor criterion, there was no clinical evidence of carditis, but echocardiographic interrogation revealed subclinical carditis or valvitis.²² If these patients had not been investigated echocardiographically, they would have gone undiagnosed, would not have received secondary prophylaxis beyond 5 years, and could end up with

rheumatic heart disease, allegedly without any past history of ARF! Our study shows that two-fifths of our patients, had we relied on traditional auscultatory findings, would not have been diagnosed with carditis had they not also been investigated with echocardiography. We also identified four patients with severe mitral regurgitation who were referred for surgical repair.²² Cotrim et al³⁷ concluded that echocardiography, if performed early, is very important in all children suspected to have acute rheumatic fever, particularly because MR can be demonstrated by colour flow mapping in the absence of any cardiac murmur. Wilson and Neutze³⁸ supported this conclusion; endorsing the fact that pulsed and colour Doppler echocardiography provide a method with which to detect minor degree of pathological regurgitation in the absence of characteristic clinical signs. The addition of echocardiographic interrogation before diagnosing carditis, therefore, not only prevents clinical overdiagnosis but also identifies those subclinical cases of carditis and valvitis that would otherwise pass undiagnosed and without prophylaxis and thus avoids underdiagnosis. We contend, therefore, that echocardiography can play an important role in the early and precise diagnosis of carditis, and should be included as part of the Jones criterions. Despite the fact that ECHO can diagnose carditis more accurately than traditional auscultatory findings and can prevent both over diagnosis and under diagnosis, it is not included in Jones criteria for the fear of overdiagnosis.

ISOLATED CARDITIS

Rheumatic carditis is almost always associated with valvulitis. Isolated myocarditis or pericarditis without valvulitis is rarely, if ever, due to ARF. So, the finding of valvular involvement is critical and is greatly aided by non-invasive ECHO. Although ECHO, particularly accompanied by Doppler studies, offers greater sensitivity and specificity for the assessment of valvular regurgitation, it need not be considered essential for the diagnosis of ARF by experienced primary care physicians, especially in settings where the disease is common and medical resources limited. Nonetheless, cardiologists proficient in echo Doppler technology, now use this method routinely to distinguish abnormal from physiologic valve leaks more sensitively and accurately than is possible by auscultation alone. Despite the relatively good prognosis of “silent” rheumatic mitral regurgitation, ECHO does, indeed, provide an accurate assessment of the presence and severity of valvulitis, especially in an era when cardiac auscultation has been taught less extensively and is used with less confidence by young clinicians. In any case, it is doubtful that a powerful diagnostic tool such as ECHO will be neglected in the assessment of valvular disease wherever the instrument is available, and certainly where its expense may not be too great a concern.³⁶

As in our study²⁹ 108 cases had subclinical carditis detected on ECHO by Vijaya’s ECHO criteria. Out of which 56 were Jones +ve and 52 cases were Jones negative. Probably these

Table 5: Changes in major criteria from 1944 to 2002 and proposal for 2010

Symptoms	1944	1956	1965	1984	1992	2002	2010
1. Carditis	Major	Major	Major	Major	Major	Major	Major
2. Polyarthritits	Major	Major	Major	Major	Major	Major	Major
3. Polyarthralgia	Major	Minor	Minor	Minor	Minor	Minor	Minor
4. Chorea	Major	Major	Major	Major	Major	Major	Major
5. Subcutaneous nodules	Major	Major	Major	Major	Major	Major	Major
6. Erythema Marginatum	Major	Major	Major	Major	Major	irrelevant	irrelevant
7. ECHO evidence of carditis	-	-	-	-	-	Major (proposed)	Major

large groups of patients are the ones who present later as RHD without the past history of ARF and do not receive secondary prophylaxis. If this large chunk of patients (32.5%) with subclinical carditis in our study could be put on adequate duration of secondary prophylaxis, probably can prevent the recrudescence of rheumatic activity. It is the lack of penicillin prophylaxis rather than failure of penicillin. The cost of ECHO at the beginning of the disease and the cost of Penicillin prophylaxis is negligible, when compared to human suffering and cost of management of RHD with surgery or without surgery.

Hence uncritical adherence to the revised Jones criterions for the diagnosis of ARF may lead to gross under diagnosis among the children with polyarthralgia and over diagnosis in those in whom carditis is reported on the basis of clinical examination. Therefore echocardiographic evidence of carditis or valvitis should be given its due importance. If we are to avoid morbidity, mortality, and unnecessary expenditure on sophisticated treatment, an early and precise diagnosis of carditis is very important.

The echocardiogram is a very simple, non-invasive, reproducible and a useful tool for making an early and precise diagnosis of carditis in the setting of acute rheumatic fever. We submit that, when the Jones criterions undergo their next revision, then echocardiography should be included as necessary for the diagnosis of carditis.

The committee for Jones' criteria is rightly skeptical for inclusion of regurgitation, as it can occur in many other conditions other than ARF leading to over diagnosis. Hence we propose ECHO evidence of carditis as diagnosed by Vijaya's ECHO criteria to be added as major criteria instead of Erythema Marginatum which is irrelevant (Table 5).

Even though ECHO Doppler is very important in the diagnosis and management of most valvular disorders, its inclusion in the Jones criteria for the diagnosis of ARF will need some caution and should be on the basis of epidemiological burden of disease and socio-economic status of the various countries. As ECHO is currently the investigation of choice to diagnosis valvular involvement, it will have a role in India

with widespread access to health care and with low cost of Echo compared to cost of treatment.

ECHO can protect patients with clinical carditis from being misdiagnosed and protect them from inadequate secondary prophylaxis regimens. In India the incidence of ARF and prevalence of RHD is very high in some places and access to good medical care and echo are limited in remote areas. Also the disease is more aggressive leading to juvenile mitral stenosis and incidence of recrudescence of rheumatic activity is also high which needs prolonged prophylaxis. Many patients present with recurrences and are likely to have established heart disease. The cost and additional workload imposed on tertiary care centers is another major issue. Hence prophylaxis is initiated in both groups, that is, in those with or without carditis and an echo could be better utilized at the time of discontinuation of prophylaxis. Echocardiography during acute attack therefore cannot be recommended as a routine modality for investigating ARF in developing countries at present. It is needless to emphasize that the role of echocardiography in the diagnosis and management of established RHD remains unquestioned in any population.

WHAT IS THE LIKELY ROLE OF ECHOCARDIOGRAPHY IN THE MANAGEMENT OF ARF IN FUTURE?

Early and precise diagnosis of carditis in ARF though difficult is very important to prevent the serious consequences, morbidity and mortality in young. Vijay's ECHO criteria play an important role in precise diagnosis of carditis/subclinical Valvulitis. These subclinical changes detected only by ECHO, can persist and probably belong to large group of patients who present later as RHD without the past history of ARF and prophylaxis. Therefore ECHO should be included as a major criterion in Jones criteria. Is detecting "ECHO detectable" subclinical carditis of clinical benefit? Yes the presence of carditis is a reason for lifelong prophylaxis? Therefore ECHO can bring more number of patients of ARF in the net of secondary prophylaxis in developing countries doing ECHO at the time of discontinuing prophylaxis might make more sense what is the impact of ECHO? The patients with carditis are more likely to be detected during their first attacks of ARF detecting subclinical carditis will prevent from a more relaxed

and inappropriate secondary prophylaxis there is a significant prognostic implication of finding a normal heart or finding unrelated causes of murmurs in this population. Echo assists in deciding the duration of secondary prophylaxis, probably can prevent the recrudescence of rheumatic activity. The recrudescence of rheumatic activity and further damage to valves is due to the lack of penicillin prophylaxis rather than failure of penicillin.

The ECHO can be used with gratifying result for risk stratification of the patient once afflicted with ARF. The presence of carditis in first attacks more prone to recurrent attacks and frequent carditis in subsequent attacks. Number of ARF recurrences are harmful and constitute the most important prognostic factor. Recurrences increase cardiovascular mortality and residual heart disease.

Fidelity of secondary prophylaxis: MR disappeared in 70% of patients on regular prophylaxis and prevents or at least reduces the number of recurrences, facilitates resolution of previous damage. Number of ARF recurrences these subclinical changes detected only by echo, can persist and probably belong to large group of patients who present later as RHD without the past history of ARF and prophylaxis. Therefore echo should be included as a major criterion in Jones criteria, so that it will change the epidemiological face of ARF and RHD completely as more patients will be brought into the net of penicillin prophylaxis. 'Rheumatic fever licks the joints but bites the heart'. Clinical profile of ARF is changing; adherence to revised Jones criteria may lead to under diagnosis among Indian children with polyarthralgia and over diagnosis in clinically diagnosed carditis. To avoid morbidity, mortality, heavy expenditure on sophisticated treatment with balloon and valve replacement, an early precise diagnosis of ARF and secondary prophylaxis is very important and ECHO is a very simple, noninvasive, reproducible and useful investigation in this endeavor. ECHO has enhanced our understanding of the pathophysiology of ARF^{10,41,47,48} and chronic RHD^{49,50} and is commonly used in the evaluation of patients with acute rheumatic fever. The dominant role of valvular pathology, rather than myocardial disease, in the clinical manifestation of RHD is now well established. ECHO is useful for confirming clinical findings, allows assessment of the severity of regurgitation, chamber size and ventricular function and the presence and size of pericardial effusion.⁴⁶ In addition ECHO may exclude mitral and/or aortic regurgitation (and therefore rheumatic valvulitis) as the cause of cardiac murmur in some patients with suspected acute rheumatic fever.⁵¹

The time has come to stop blame game. When the helpless child with severe carditis with CHF is brought to the hospital; the cardiologist blames the clinician for referring the child late; but the physician blames the illiterate parents and the parents in turn blames the government for poor socioeconomical conditions and unhygienic living conditions. It is high time

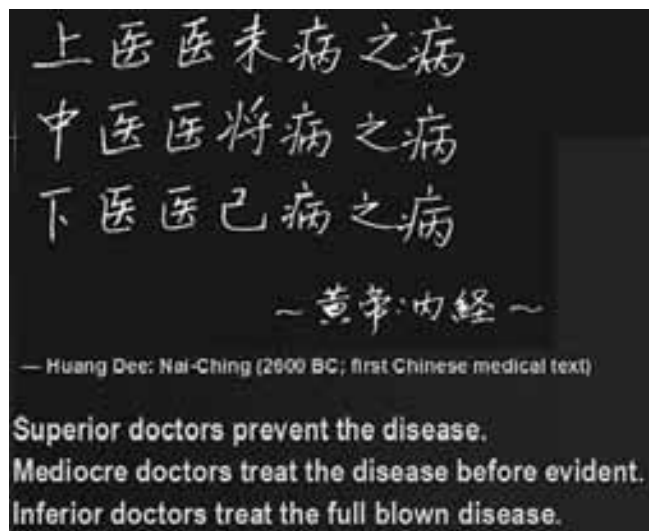
we stopped blaming each other in India and utilize the modern facility like ECHO to make early and precise diagnosis to treat the children with carditis appropriately in time.

SUMMARY CONCLUSION

- Adherence to revised Jones criteria may lead to under diagnosis among the Indian children with polyarthralgia and over diagnosis in clinically diagnosed carditis.
- Early and precise diagnosis of carditis in ARF though difficult is very important to prevent the serious consequences, morbidity and mortality in young.
- Valvular regurgitation (rather than myocarditis or pericarditis) is the important abnormality in acute rheumatic carditis. The assessment of mechanism and severity of MR and/AR has prognostic significance.
- ECHO has enhanced our understanding of the pathophysiology of carditis. ECHO alone can detect the characteristic features like thickened leaflets of the aortic and mitral valves, reduced mobility, beaded appearance, hyper-echogenicity of the submitral structures, mitral valvar prolapse with mitral regurgitation which are pathognomonic of carditis in ARF.
- Vijay's ECHO criteria play an important role in precise diagnosis of carditis/subclinical Valvulitis. These subclinical changes detected only by ECHO, can persist and probably belong to large group of patients who present later as RHD without the past history of ARF and prophylaxis.
- Early and precise diagnosis of carditis/subclinical valvulitis in ARF is possible only with ECHO. For decades we have been taught that 50% of RHD patients do not have past history of ARF. ECHO evidence shows that probably these are the subclinical cases which have been missed by clinicians. Hence, ECHO can bring more number of patients of ARF in the net of secondary prophylaxis in developing countries
- To avoid morbidity and mortality and heavy expenditure incurred on sophisticated treatment with balloon or valve replacement by the Government and family, an early precise diagnosis of ARF and secondary prophylaxis is very important and echo is a very useful investigation in this direction.
- The echocardiogram is a very simple, non invasive, reproducible and a useful tool for making such an early and precise diagnosis of carditis in the setting of acute rheumatic fever.
- The ECHO can be used with gratifying result for risk stratification of the patient once afflicted with ARF
- ECHO criteria are very essential to prevent the morbid-

ity and mortality in young. Hence when the Jones criterion undergoes next revision, then echocardiographic criteria should be included as necessary for the diagnosis of carditis in ARF.

- ECHO can change the epidemiological face of ARF in India.



REFERENCES

1. Sanyal SK, Thapar MK, Ahmed SH, Hooja V, Tewari P. The initial attack of acute rheumatic fever during childhood in North India; a prospective study of the clinical profile. *Circulation* 1974;49:7-12.
2. Sanyal SK, Berry AM, Duggal S, Hooja V, Ghosh S. Squeal of the initial attack of acute rheumatic fever in children from north India. A prospective 5-year follow-up study. *Circulation* 1982; 65: 375-9.
3. Padmavathi S. Present status of Rheumatic fever and rheumatic heart disease in India. *Indian Heart Journal* 1995;47: 395-398.
4. Padmavathi S. Rheumatic fever and rheumatic heart disease in India at the turn of the Century. *Indian Heart Journal* 2002; 53: 35-37.
5. Hippocrates. The genuine works of Hippocrates (translated from Greek by Francis Adams) New York. Wood 1986; 192-273.
6. Jones TD: Diagnosis of rheumatic fever. *JAMA* 1944; 126: 481-484.
7. Ad hoc committee on Rheumatic Fever and Bacterial Endocarditis of the American Heart Association. Jones criteria (revised) for guidance in the diagnosis of Rheumatic Fever. *Circulation* 1965; 32: 664-668.
8. Committee on Rheumatic Fever and Bacterial Endocarditis of the American Heart Association. Jones criteria (revised) for guidance in the diagnosis of rheumatic fever. *Circulation* 1984; 69: 203A-208A.
9. Special writing group of the Committee on Rheumatic fever, Endocarditis and Kawasaki disease of the Council of Cardiovascular disease in the young of the American Heart Association. Guidelines for the diagnosis of rheumatic fever: Jones criteria: 1992 update. *JAMA* 1992; 268: 2069–2073.
10. Narula J, Chandrasekhar Y, Rahimtoola S. Diagnosis of active rheumatic carditis. The echoes of change. *Circulation* 1999; 100:1576-1581.
11. IB Vijayalakshmi. Rheumatic Fever, Rheumatic Heart Disease Registry and Control Program. IB Vijayalakshmi ed. Acute Rheumatic Fever and Chronic Rheumatic Heart disease. 2011. Jaypee Brothers Medical Publishers. India. P324-336.
12. Mishra TK, Acute Rheumatic Fever and Rheumatic Heart Disease: Current Scenario. *Indian Academy of Clinical Medicine* 2007; 8:324-30.
13. Bhava M., Panwar S. Beniwal RI, Panwar RB. High prevalence of rheumatic heart disease detected by echocardiography in school children. *Echocardiography* 2010; 27: 448–453.
14. Misra M, Mittal M, Singh RK, Verma AM, Rai R. et al. Prevalence of rheumatic heart disease in school going children of eastern Uttar Pradesh. *Indian Heart J* 2007; 59: 42–43.
15. Smita M. Can we change the epidemiological trend of rheumatic heart disease in India? IB Vijayalakshmi ed. Acute Rheumatic Fever and Chronic Rheumatic Heart disease. 2011. Jaypee Brothers Medical Publishers. India; P 47-57.
16. Lalchandani A, Kumar HRP, Alam SM. Prevalence of rheumatic fever and rheumatic heart disease in rural and urban schoolchildren of district Kanpur. *Indian Heart Journal* 2000; 50:672.
17. Kumar RK, Mary P, Paul TF. RHD in India: Are we ready to shift from secondary prophylaxis to vaccinating high risk children? *Current Science* 2009; 97:397-404.
18. Bharani A Prevalence of Rheumatic Fever/Rheumatic Heart Disease in India: Lessons From Active Surveillance and A Passive Registry. *J Am Coll Cardiol* 2010;55:A151.E1415
19. Agarwal AK, Yunus M, Ahmad J, Khan A. Rheumatic heart disease in India. *J R Soc Health* 1995; 115:303-309.
20. Grover A, Dhawan A, Iyengar, SD, Anand IS, Wahi PL, Ganguly, NK. Epidemiology of rheumatic fever and rheumatic heart disease in a rural community in northern India. *Bull WHO* 1993; 71:59-66.
21. Jacob J V, Gomathi M. Declining prevalence of rheumatic heart disease in rural schoolchildren in India: 2001-2002. *Indian Heart J* 2003; 55:158-60.
22. Vijayalakshmi IB, Mithravinda J, Deva AN. The role of echocardiography in diagnosing carditis in the setting of acute rheumatic fever. *Cardiol Young* 2005; 15: 583–588.
23. WHO. Rheumatic fever and rheumatic heart disease: report of a WHO Expert Consultation, Geneva 29 October - 1 November 2001. WHO technical report series; 923.Geneva: World Health Organisation, 2004.
24. Saxena A, Kumar RK, Gera RP et al. Consensus Guidelines on Pediatric Acute Rheumatic Fever and Rheumatic Heart Disease Working Group On Pediatric Acute Rheumatic Fever And Cardiology Chapter Of Indian Academy Of Pediatrics. *Indian Pediatr* 2008; 45:565-73.
25. Carapetis JR, Brown A, Wilson NJ, Edwards KN; Rheumatic Fever Guidelines Writing Group. An Australian guideline for rheumatic fever and rheumatic heart disease: an abridged outline. *Med J Aust* 2007; 186:581-6.
26. St. Clair EW, Oddone EZ, Waugh RA, Corey GR, Feussner JR.

- Assessing house staff diagnostic skills using a cardiology patient simulator. *Ann Intern Med* 1992; 117:751–756.
27. Mangione S, Nieman L, Gracely E, Kaye D. The teaching and practice of cardiac auscultation during internal medicine and cardiology training. *Ann Intern Med* 1993; 119:47–54.
 28. Butterworth JS, Reppert EH. Auscultatory acumen in the general medical population. *JAMA* 1960; 174:32–34.
 29. Vijayalakshmi IB, Vishnuprabhu RO, Chitra N, Rajasri R, Anuradha TV. The efficacy of echocardiographic criteria for the diagnosis of carditis in acute rheumatic fever. *Cardiol Young* 2008; 18: 586–592.
 30. Narula J, Chopra P, Talwar KK, Vasana RS, Reddy KS, Tandon R, Bhatia ML, Southern JF. Does endomyocardial biopsies aid in the diagnosis of acute rheumatic carditis? *Circulation* 1993; 88:2198–2205.
 31. Veasy LG, Wiedmeier SE, Orsmond GS, Ruttenberg HD, Boucek MM, Roth SJ, Tait VF, Thompson JA, Daly JA, Kaplan EL, Hill HR. Resurgence of acute rheumatic fever in the intermountain area of the United States. *N Engl J Med* 1987; 316:421–427.
 32. Folger GM, Hajar R, Robida A, Hajjar HS. Occurrence of valvular heart disease in acute rheumatic fever without evident carditis: colour-Flow Doppler identification. *Br Heart J* 1992; 67:434–439.
 33. Abernathy M, Bass N, Sharpe N, Grant C, Neutze J, Clarkson P, Greaves S, Lennon D, Snow S, Whally G. Doppler echocardiography and the early diagnosis of carditis in acute rheumatic fever. *Aust N Z J Med* 1994; 24: 530–535.
 34. Wilson NJ, Neutze JM. Echocardiographic diagnosis of subclinical carditis in acute rheumatic fever. *Int J Cardiol* 1995; 50:1–6.
 35. Folger GM Jr, Hajar R. Doppler echocardiographic findings of mitral and aortic valvular regurgitation in children manifesting only rheumatic arthritis. *Am J Cardiol* 1989; 63:1278–1280.
 36. Veasy LG, Tani LY, Hill HR. Persistence of acute rheumatic fever in the intermountain area of the United States. *J Pediatr* 1994; 125: 673–674.
 37. Cotrim C, Macedo AJ, Duarte J, Lima M. The echocardiogram in the first attack of rheumatic fever in childhood. *Rev Port Cardiol* 1994; 13: 563, 581–586.
 38. Wilson NJ, Neutze JM, Voss LM, Lennon DR, Ameratunga RV. Colour Doppler demonstration of pathological valve regurgitation should be accepted as evidence of carditis in acute rheumatic fever. *New Zealand Medical Journal* 1995; 108: 200. Also in *New Zealand Medical Journal* 1998; 111 Suppl: No 1067:10.
 39. Minich LL, Tani LY, Pagotto LT, Shaddy RE, Veasy LG. Doppler echocardiography distinguishes between physiologic and pathologic “silent” mitral regurgitation in patients with rheumatic fever. *Clin Cardiol* 1997; 20: 924–926.
 40. Veasy LG. Echocardiography for diagnosis and management of rheumatic fever. *JAMA* 1993; 269: 2084.
 41. Vasana RS, Shrivastava S, Vijayakumar MD, Narang R, Lister BC, Narula J, et al. Echocardiographic evaluation of patients with acute rheumatic fever and rheumatic carditis. *Circulation* 1996; 94: 73–82.
 42. da Silva CH. Rheumatic fever: A multicenter study in the state of Sao Paulo. Pediatric Committee - Sao Paulo Pediatric Rheumatology Society. *Rev Hosp Clin Fac Med Sao Paulo* 1999; 54:85-90.
 43. Elevli M, Celebi A, Tombul T, Gokalp AS. Cardiac involvement in Sydenham’s chorea: Clinical and Doppler echocardiographic findings. *Acta Paediatr* 1999; 88:1074-1077.
 44. Figueroa FE, Fernandez MS, Valdís P, Wilson C, Lanás F, Carrión F, et al. Prospective comparison of clinical and echocardiographic diagnosis of rheumatic carditis: Long term follow up of patients with subclinical disease. *Heart* 2001; 85:407-10.
 45. Ozkutlu S, Ayabakan C, Saraçlar M. Can subclinical valvitis detected by echocardiography be accepted as evidence of carditis in the diagnosis of acute rheumatic fever? *Cardiol Young* 2001; 11:255-60.
 46. Stollerman GH. Can we eradicate rheumatic fever in the 21st century? *Indian Heart J* 2001; 53:25-34.
 47. Essop MR, Wisenbaugh T, Sareli P. Evidence against a myocardial factor as the cause of left ventricular dilation in active rheumatic carditis. *J Am Coll Cardiol* 1993;22:826–829.
 48. Marcus RH, Sareli P, Pocock WA, et al. Functional anatomy of severe mitral regurgitation in active rheumatic carditis. *Am J Cardiol* 1989; 63: 577–584.
 49. Gordon SP, Douglas PS, Come PC, et al. Two-dimensional and Doppler echocardiographic determinants of the natural history of mitral valve narrowing in patients with rheumatic mitral stenosis: implications for follow-up. *J Am Coll Cardiol* 1992;19:968–973.
 50. Sagie A, Freitas N, Padial LR, et al. Doppler echocardiographic assessment of long-term progression of mitral stenosis in 103 patients: valve area and right heart disease. *J Am Coll Cardiol* 1996; 28:472–479.
 51. Regmi PR, Pandey MR. Prevalence of rheumatic fever and rheumatic heart disease in school children of Kathmandu city. *Indian Heart J* 1997; 49:518–520.